

Original Research

# Changing Magnetic Fields in the Treatment of Compressive Fractures in the Cervical Spine – Case Description

J. Pasek<sup>1\*</sup>, S. Kwiatek<sup>1</sup>, T. Pasek<sup>2</sup>, I. Kozłowska-Kwiatek<sup>1</sup>,  
P. Kwiatek<sup>1</sup>, K. Sieroń-Stołyński<sup>1</sup>, A. Sieroń<sup>1</sup>

<sup>1</sup>Department and Clinic of Internal Diseases, Angiology and Physical Medicine,  
Chair of Internal Diseases and the Center for Laser Diagnostics and Therapy,  
Silesian Medical University in Katowice, Stefana Batorego 15, 41-902 Bytom, Poland

<sup>2</sup>Department of Rehabilitation, St. Barbara Specialized Regional Hospital No. 5. Sosnowiec, Poland

Received: 3 November 2008

Accepted: 24 February 2009

## Abstract

Many people spend about 80% of their free time practicing sports, including skiing, which in many cases can cause changes in the skeletal system, muscular system and other organs. The aim of this article is to discuss the treatment of a 25-year-old man who suffered a compressive fracture of the C6 vertebra with paresis of the ulnar nerve. The treatment used physiotherapy with changing magnetic fields (magnetostimulation, magnetolaserotherapy, kinesitherapy exercises) with good effects. On the basis of the results we discovered that these treatment methods can accelerate the time of treatment and increase quality of life.

**Keywords:** physiotherapy, changing magnetic fields, compressive fractures of the cervical spine

## Introduction

The natural environment has a special influence on the human organism, e.g. on correct physical and mental development. The environment consists of many ecological factors that influence life, health and sanity. Hippocrates said that “*Understanding of influence of environment on human organism is a basis of medical art.*” Multidimensional sport activity has various influences on the health and life of a human being. Among the most popular outdoor winter activities is skiing. The popularity and development of this discipline has increased the risk of accidents for professionals and amateurs. In many cases this results in irreparable change [1, 2].

In relation to the frequency of sport accidents, the risk of spinal posttraumatic neurological complications is still increasing [3]. Posttraumatic vertebral damages in cervical spine can cause irreparable disability. Early and proper diagnostics of posttraumatic spinal damage is necessary to get good neurological and functional results from treatment [4, 5].

The cervical spine is the least protected and covered spinal segment. Fractures are most often localized in this fragment. Protruding over the body, and loaded by head and neck weight doesn't help it to withstand sudden axial and linear forces during an accident. Delicate construction of the vertebral anatomic parts and considerable mobility are a cause of damage to the anatomical structure, functional stability and protection for blood vessels and the most important nerves [2, 6].

\*e-mail: address: jarus\_tomus@o2.pl



Spinal traumas in the cervical spine between C1 to C5 are known as high damages, and traumas between C5 to Th1 are known as low damages. This classification is a result of symptoms in neurological complications after damage. A few years ago the main cause of spinal damages were decays from height (jumps to water – about 60%) and road accidents (30%) and others (about 10%) [7]. Presently the number of road accidents is increasing rapidly and they are becoming the main basis for traumatic cervical spinal damages [3, 7].

Compressive fracture is observed when forces are making a pressure in axis of spine and lead to crush the vertebral corpse. Higher endurance in posterior parts of vertebra protects those fragments and leads to destruction in anterior parts, making vertebra a wedge. Great force of damage can lead to breakage of the vertebral structure and lead to damage of spinal cord with all the neurological complications. Compressive fracture rarely leads to neurological complications in spinal cord and nerves. The narrowest spine canal is in the superior and medial part of the thoracic spine, so tolerance for damage is the lowest in the whole spinal cord. Even little fragments of bones dislocated toward the spinal canal can cause paresis and neural defects [2, 4, 8].

A basic method for surgical treatment of a compressive fracture with dislocation of little fragments of bone to the spinal canal is the removal of damaged vertebral corpus with full protection of the spine and radices of the nerve and internal stabilization with the use of bone transplant and an internal stabilizer - titanium arthroplasty implant. Use of metal elements like screws, metallic implants or stabilizing plates often makes it difficult for early physiotherapy. Every method that can accelerate the process of convalescence, reduce neurological damage or improve therapeutic effects should be considered, since 50% of serious traumatic damages of cervical vertebra are simultaneous with damages of cranium, thorax, abdomen and limbs [2, 9, 10].

Magnetostimulation is one method that, due to many positive therapeutic effects, could be used in early treatment directly after operation [11, 12].

In the few last years many studies have considered mainly the influence of magnetic fields with low frequencies on living organisms and the nervous system [13-16]. Many positive effects have been documented, for example an increase of neural conduction and an increase of metabolic and biochemical functions. Those effects are used in treatment of brain stroke, Parkinson's disease and traumatic dysfunction of the spine. Described effects lead to an acceleration of normal functioning regain in the damaged peripheral nerves [17, 18]. Changing magnetic fields as a magnetostimulation are the most popular methods of treatment used in neurology and orthopedics, mainly causing the return of the analgetic, nutritive and regenerative functions [3, 13, 14, 16].

### Case Description

The effectiveness of the variable magnetic fields with early kinetic rehabilitation as kinesytherapy exercises was exemplified in the treatment of a 25-year-old male patient admitted to the Clinic and Department of Internal Diseases, Angiology and Physical Medicine in Bytom. About 2 weeks prior to admission, the patient had a ski accident during which he was subject to a compressive fracture of cervical vertebra C6. As a result of the fracture, the paresis of the ulnar nerve was observed. The fracture of cervical vertebra was surgically treated in The Unfallkrankehaus in Salzburg with a titanium stabilizer implanted between C5-C7 (Fig. 4). After the operation the patient had an orthopedic collar that was stabilized his neck for 6-8 weeks. Those activities enabled quick mobilization and transport to Poland.

During the radiological examination in our Clinic we observed an internal titan arthroplasty in the fracture site (C6) with fracture fissure (Figs. 1-3). In the neurological examination paresis of the ulnar nerve was observed, especially in flexion of the carpal joint and during precise right-hand movements. The patient complained of neck pain as well as bilateral sensations along the ulnar nerves and hyperaesthesia of the left side of his body.

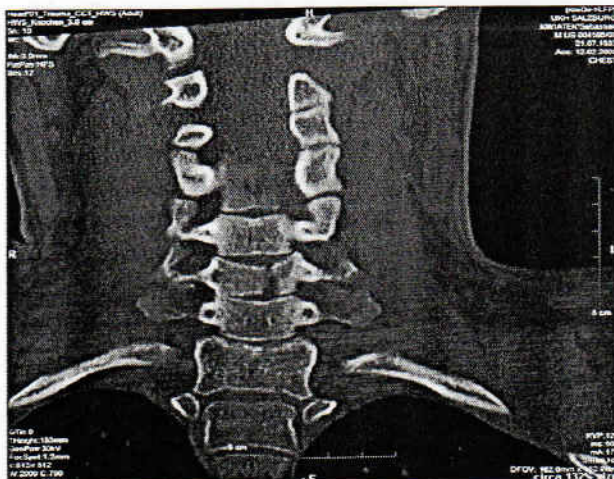


Fig. 1. CT image of cervical spine in frontal view. C6 vertebra with posttraumatic fracture fissure.

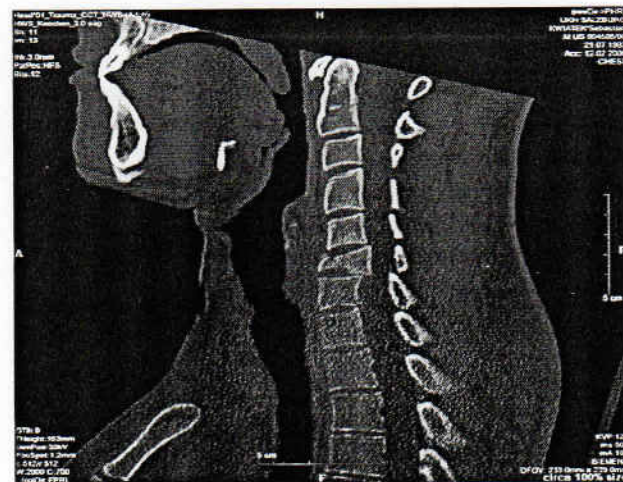


Fig. 2. CT image in Lateral view with compressive fracture of C6.



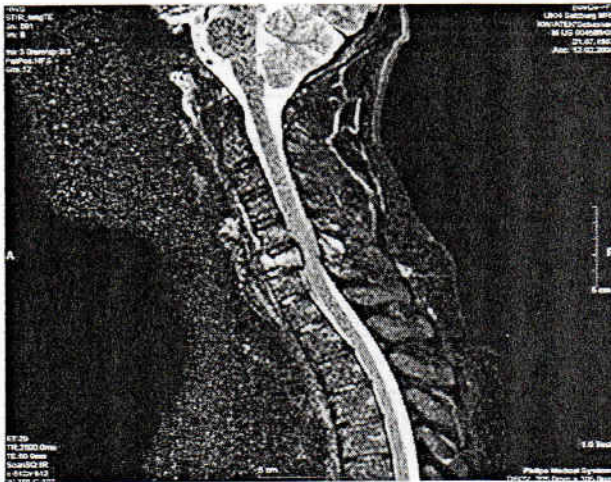


Fig. 3. MRI STIR image of cervical spine in a lateral view. View of compressive fracture of C6 with pressure on the spinal cord.

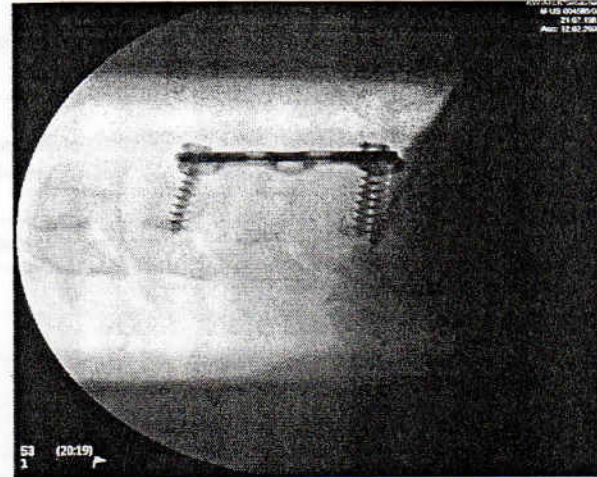


Fig. 4. X-Ray image taken after operation. Visible fracture fissure and titanium plate between C5-C7.

### The Treatment

Treatment of traumatic spinal damage with neurological complications without physiotherapy is not possible. The main aim of rehabilitation is fast reconstruction of full mobility of the joints and also to regain muscle strength. Moreover, it is important to take care of the muscle groups and train them with exercises that increase muscle strength and also reduce the risk of secondary deformation of the limbs. Rehabilitation should be started as fast as possible after the trauma, even immediately after discharge.

Rehabilitation in this case was started 1 day after admission to the hospital. Magnetostimulation was performed in 2 series, with 10- and 12-minute therapeutic sessions per day. During the weekend the patient was treated only with the exercises. After the first 10 days the patient had a 10-day pause in magnetostimulation. Viofor JPS Classic was applied in magnetostimulation and Viofor JPS Laser was used in magnetolasertherapy. In our study the treatment was performed with the following applicators:

1. Big applicator – program M1 P2 with intensity 8 (whole body),
2. Small applicator – program M2 P2 intensity 6 (only on a paralyzed limb),
3. Clinical applicator with program M1 P2 with intensity 8 (torus applicator only on the neck),
4. Magnetolaser IR (used on paralyzed ulnar nerve) – 8 minutes, density of radiation was  $3.0 \text{ J/cm}^2$ , average power was 15.0 mW.

M1 – application with constant intensity All of the time during treatment.

M2 – application with increasing intensity for 12 minutes.

P2 – system JPS with two modal pulses with frequency 180 – 195 Hz.

During magnetolaserotherapy, early kinesitherapy was performed. Two times per day the patient exercised with passive exercises at the beginning and with the stress put onto all the physiological motion planes. Passive exercises

were performed from proximal to distal parts of the limb, with complete stability of the proximal part of this limb. All of the exercises led to better blood circulation and nutrition of the tissues, especially in the muscles and joints. The main aim of passive exercises was to prepare all of the muscle groups and joints to their functioning on their own, which increased in time in correlation with the improvement of neurological function. In the next few days we gradually added passive-active and active exercises for the paralyzed limb.

On day 4 we developed kinesitherapy and attached resistant exercises with an increasing load. We engaged the patient in a self-made daily activity (catching, dropping, combing, washing and others) and to use the paralyzed limb. All kinesitherapy was performed based on the conception of forced using – CIMT based on neuroplasticity of the brain. Even a vestigial move was improving all of the patient's functions [14, 19].

To decrease the effect of cooling of the paralyzed limb we used a woolen sleeve. It is important that the patient, after application of the first 6 sessions, significantly decreased the doses of NSAIDs and after the next 10 sessions he finished NSAIDs intake. One of the side effects was a feeling of pins and needles in the ulnar nerve.

Before treatment the patient's full shortened scale of pain intensification was recorded (*VRS - Verbal Rating Scale*). The ailments on the intensification of the pain were evaluated as 3-4 (strong) (4 - the highest degree in the scale). The authors examined the muscular strength according to the Lovet's scale, also in the individual joints (shoulder, elbow, carpal joint) and measured the range of movements of the paralyzed limb (Table 1).

After 10 and 20 procedures of magnetostimulation the authors estimated the pain ailments with the use of a VRS scale, the mobility joints and the strength of muscles in the paralyzed limb. The patient after the first series of interventions quit to take the NSAIDs. The only subjective side effect was the feeling of formication along the ulnar nerve



Table 1. The measurements of mobility of the joints and the evaluation of muscle strength of the paralyzed limb in the patients after a compressive fracture in the cervical spine.

	Mobility of joints before rehabilitation	Evaluation of the muscle strength before rehabilitation	Mobility of joints after rehabilitation	Evaluation of the muscle strength after rehabilitation
Shoulder joint				
Flexion	35°	2	90°	4
Elevate by flexion	35°	2	180°	4
Extension	0°	1	25°	2
Abduction	20°	2	90°	4
Elbow joint				
Flexion	120°	4	150°	5
Extension	0°	3	0°	4
Capral joint				
Flexion	50°	3	65°	4
Extension	30°	2	60°	3
Adduction	10°	1	20°	1
Abduction	10°	1	15°	1

after magnetolaserotherapy, which was subject to a complete regression after the second therapeutic session.

### Discussion

Well understood rehabilitation should be complex and early [20, 21]. Cooperation of changing magnetic fields and physiotherapy is valid in the treatment of paresis. The use of this treatment in this patient caused a regained function of the ulnar nerve without all damaged nerves regenerated.

The presented case shows the potential effectiveness of new physical modalities in the complex treatment of compressive fractured cervical vertebrae [13, 18]. Good treatment results were also caused by analgetic, anti-inflammatory, antioedematous and nutritive effects, and also by increase of blood circulation and nutrition of the nerves. After treatment we observed only trace strength reduction of the palm's function with a low paresis of the extensors muscles [3, 18, 22, 23].

Our treatment resulted in this case in a little number of side effects, and good toleration which shows that variable magnetic fields combined with physiotherapy are not very invasive and are promising in the treatment of patients with traumatic damage to the cervical spinal cord.

### Conclusions

Variable magnetic fields of low frequencies combined with an active early kinesiotherapy have a positive influence

on the course of disease and the whole treatment. All presented methods allow us to get better treatment results. Important is the analgetic effect of magnetolaserotherapy, which is a factor increasing the chance of early mobilization, reduction of anti-inflammatory drugs doses.

### References

1. KIWERSKI J. Epidemiology of vertebral column injury. *Prewencja i Rehabilitacja*. 3(9), 1, 2005 [In Polish].
2. KIWERSKI J. Non-homogeneity of damage vertebral column with compression mechanism. *Chir. Narz. Ruchu Ortop. Pol.* 3, 186, 1986 [In Polish].
3. SIEROŃ A., JĘDRZEJEWSKA A., DOBOSIEWICZ K. Magnetic stimulation with ionic cyclotron resonance as a new method of supporting treatment of neurological complications in bone fracture. *Neurologia dziecięca*. 16(31), 61, 2007 [In Polish].
4. BRACKEN M.B., SHEPARD M.J., COLLINS W.F., HOLFORD T.R., YOUNG W., BASKIN D.S. Randomized Controlled Trial of Methylprednisolone or Naloxone in the Treatment of Acute Spinal Cord Injury. *The New England Journal of Medicine*. 20(322), 1405, 1990.
5. EDWARDS D.F., HAHN M., BAUM C.M. Screening Patients with Stroke for Rehabilitation Needs: Validation of the Post-stroke Rehabilitation Guildenes. *Neurorehab Neural Repair*. 20, 42, 2006.
6. KIWERSKI J., KULIKOWSKI J. The influence of vertebral injury mechanism on the degree damage neurological elements in vertebral canal. *Chir. Narz. Ruchu Ortop. Pol.* 1, 4, 1986 [In Polish].

7. DITUNNO J.F. Jr, YOUNG W., DONOVAN W.H., CREASEY M.D. The International Standards Booklet for Neurological and Functional Classification of Spinal Cord Injury. *Paraplegia*. **32**, 70, 1994.
8. WOLDAŃSKA-OKOŃSKA M., CZERNICKI J. The application magnetic fields in rehabilitation after stroke. *Fizjoterapia*. **6** (3), 6, 1998 [In Polish].
9. SIEROŃ A., CIEŚLAR G., ŻMUDZIŃSKI J. The therapeutic influence changing magnetic fields in patients with late consequence after stroke. *Fizjoterapia*. **3**, 9, 1994 [In Polish].
10. MC AFEE P.C., YUAN H.A., FREDERIKSON B.E., LUBICKY J.P. The value of computed tomography in thoracolumbar fractures. *J.Bone Joint Sug.* **65**, 461, 1983.
11. PASEK J., MUCHA R., SIEROŃ A. Magnetostimulation – a modern form of therapy for medicine and rehabilitation. *Fizjoterapia*. **14** (4), 3, 2006 [In Polish].
12. PASEK J., PASEK T., SIEROŃ A. Home therapy with use a changing magnetic fields. *Rehabilitacja w Praktyce*. **2**(3), 50, 2007.
13. MC CAIG C.D., RAJNICEK A.M. Electrical fields, nerve growth and nerve regeneration. *Exp. Physiol.* **76**, 473, 1991.
14. PASEK J., MUCHA R., OPARA J., SIEROŃ A. Rehabilitation and physics therapy after stroke. *Rehabilitacja w Praktyce*. **2**, 35, 2007 [In Polish].
15. PASEK J., MUCHA R., SIEROŃ A. Slow changing magnetic fields in the treatment of arm brachium (radiculitis brachialis). *Acta Bio – Optica et Informatica Medica*. **2**, 93, 2006 [In Polish].
16. SIEROŃ A., OBUCHOWICZ A., BILSKA A. The application magnetic fields in the treatment of peripheral paralysis of facial nerve in-children – descript of a ceases. *Balneol. Pol.* **66** (1-2), 58, 2004 [In Polish].
17. WOLDAŃSKA-OKOŃSKA M., CZERNICKI J., KACZMAREK J. The influence of impulsation magnetic fields on the rehabilitation process in patients after stroke. *Balneol. Pol.* **39** (1-2), 73, 1997 [In Polish].
18. SIEROŃ A. The application of magnetic fields in medicine. Alfa - medica Press. Bielsko-Biała 2000 [In Polish].
19. SUPUTITADDA A., SUWANWELA N.C., TUMVITTE S. Effectiveness of constraint – induced movement therapy in chronic stroke patients. *J. Med. Assos. Thai.* **87**, 1482, 2004.
20. DISERENS K., MICHEL P., BOGUSLAVSKY J. Early mobilization after stroke: Review of the literature. *Cerebrovasc Dis.* **22**(2-3), 183, 2006.
21. GORDON N.F., GULANICK M., COSTA F. Physical Activity and Exercises Recommendations for Stroke Survivors. The Council on Nutrition, Physical Activity, and Metabolism; and the Stroke Council. *Circulation*. **109**, 2031, 2004.
22. PASEK J., MISIAK A., MUCHA R., PASEK T., SIEROŃ A. The new possibility in physics therapy – magneto-laserotherapy. *Fizjoterapia Polska*. **1**(8), 1, 2008 [In Polish].
23. PASEK J., PASEK T., SIEROŃ A. Magnetolaserotherapy in the treatment of dry dental alveolus. Description of a case. *Leczenie ran*. **5**(1), 21, 2008 [In Polish].





We would like to invite you to take part  
in the IV<sup>th</sup> International Scientific Conference  
“INLAND SHIPPING 2009”.

The Conference will take place in Szczecin, 9-10 July, 2009.  
The Conference is organized by the Institute  
of Transport Engineering in Maritime University of Szczecin.



Szczecin

**The conference is focused on:**

- Inland shipping in transport systems,
- Safety of navigation,
- Technical reliability of ships,
- Building and operation of waterways and inland ports,
- River transport of goods,
- Environment protection,
- Education of personnel,
- Legal regulations,
- International cooperation,
- Management in inland shipping,

**Articles**

Authors are asked to send abstracts of their articles to the Conference Office. The articles will be reviewed by members of the Scientific Committee.

The articles will be published in the Conference Papers in Polish, English or German.

**Presentations and exhibitions**

Companies and Institutions will be able to present every kind of products and their activities related on the topics of the conference.

**Study trip**

A study trip will take place during the Conference aiming at visiting hydrotechnics infrastructure and Szczecin Waterway Junction.

**Important Dates:**

- 31.03.2009** Registration deadline
- 20.04.2009** Full paper submission and conference fee – deadline
- 20.05.2009** Bulletin no 3. The conference program.

**Conference fee**

Conference fee is 150 EUR. It excludes accommodation fee. Organizers of the conference are able to do a hotel reservation.

**Organizing Committee**

*Chairman:*

Krzysztof Woś Inland Master PhD

*Organizer secretary:*

Kasper Jędrzychowski Eng

*Members:*


Jacek Trojanowski Inland Master PhD Eng

Jerzy Raducha M.Sc Eng

Filip Gruszczyński M.Sc

**Conference Office**

Maritime University of Szczecin  
Institute of Transport Engineering  
ul. Ludowa 7/8, 71-700 Szczecin, POLAND  
tel.: (+4891) 424-4160; fax: (+4891) 424-4169;  
e-mail: inlandsh@am.szczecin.pl  
<http://www.am.szczecin.pl/inlandshipping>



IV Międzynarodowa Konferencja Naukowa

**Inland Shipping 2009**

Szczecin, 9-10 lipca 2009

**THE ODER DAYS 2009**

Szczecin 9-12 July 2009

